

Title: Testicular tumor from a pet rabbit (*Oryctolagus cuniculus*)

Contributors: Javier Martínez-Caro¹, Laura Vilalta Solé^{2,3}, Antonio Meléndez-Lazo^{1,2}

¹T-CITO, Valencia, Spain

²Hospital Veterinario de Referencia UCV, Valencia, Spain

³Departamento de Medicina y Cirugía Animal, Universidad Católica de Valencia "San Vicente Mártir, Valencia, Spain

Specimen: Impression and fine needle aspiration cytology.

Signalment: A 6-year-old male pet rabbit (*Oryctolagus cuniculus*).

History and Clinical findings:

The patient presented with an enlarged right testicle. Otherwise, he had no previous clinical history, and his diet consists of a seed mixture, hay, and vegetables.

Physical examination revealed an enlarged right testicle, atrophy of the left testicle and increased body condition.

There were no lesions in the scrotal skin, but scrotal sac was increased in size due to testicular enlargement and it contacted with the perianal area and urethral opening. Otic secretion with pain on auricular palpation was noticed. Also, he had mild pododermatitis in both forelimbs and mild occlusive dental problems.

Diagnostic procedures:

Serum biochemistry and hematology were performed either as a minimum database of the patient and a preanesthetic evaluation. Hematology analysis showed a moderate lymphopenia, 460 lymphocytes per microliter (RI: 1,490-5,210 per microliter) and serum biochemistry results were within reference intervals. Ultrasound examination revealed an increase size of the right testicle (6 cm in diameter), the majority of the testicular parenchyma has been replaced by hypoechoic to anechoic foci of various sizes and shapes with abnormal Doppler color signal and mineralized areas. The left testicle was atrophied but with normal architecture. Prostatic abnormalities were not seen. On thoracic radiographs, metastatic lesions were not evident. Cytological examination of the otic secretion revealed the presence of *Malassezia* sp., for its morphology, most likely *M. cuniculi*.

Surgical procedure and treatment:

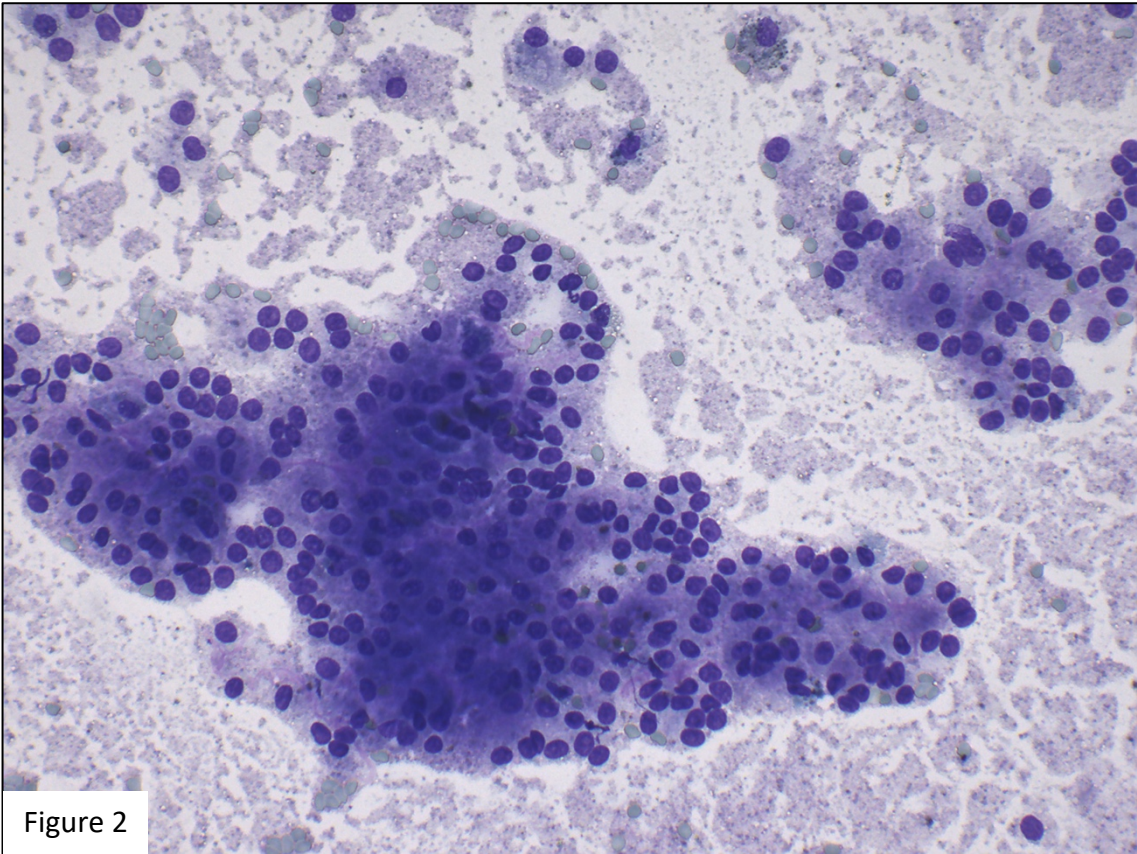
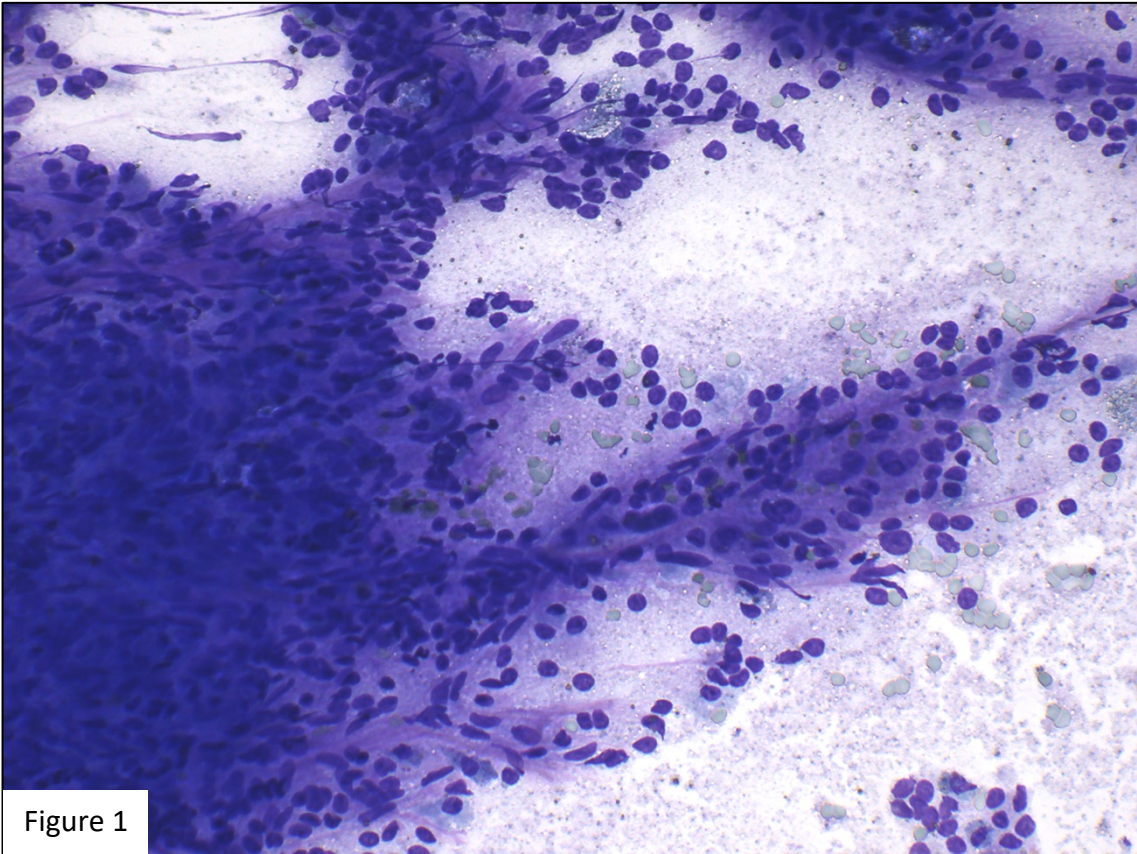
Because neoplasia was suspected, bilateral orchiectomy and scrotal ablation was performed using an open prescrotal approach under general anesthesia. Postsurgical treatment included intravenous fluid therapy, analgesia with opioid drugs (buprenorphine), NSAID (meloxicam), antibiotherapy (enrofloxacin) and prokinetics (metoclopramide).

Cytologic specimens (figures 1 to 5) were prepared using fine needle aspiration and impression techniques before formalin fixation for histopathological examination.

Questions:

1. What is your description of the cytologic findings?
2. What is your interpretation?
3. Which further tests would you recommend in order to confirm the preliminary diagnosis?

Figures 1 and 2: cytological photomicrograph of the testicular mass. Aqueous Romanowsky stain, x20 objective.



Figures 3 and 4: cytological photomicrograph of the testicular mass. Aqueous Romanowsky stain, ×40x objective.

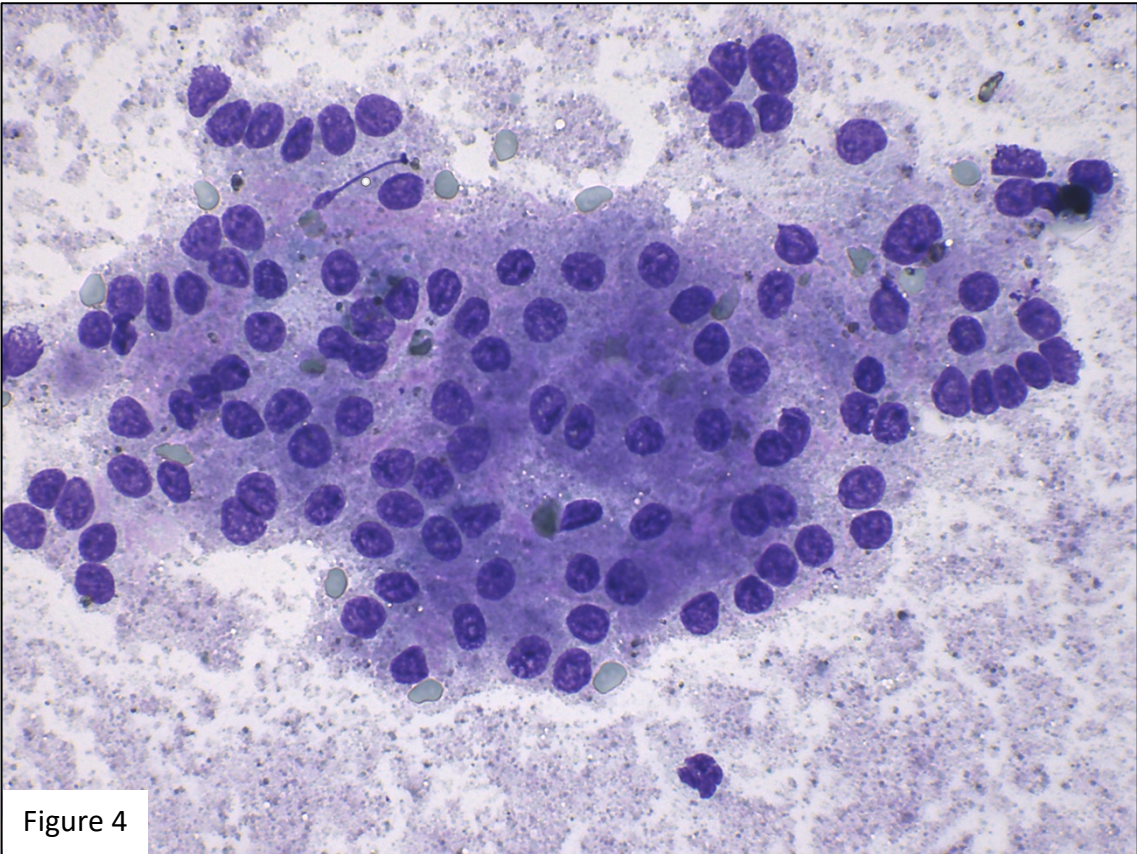
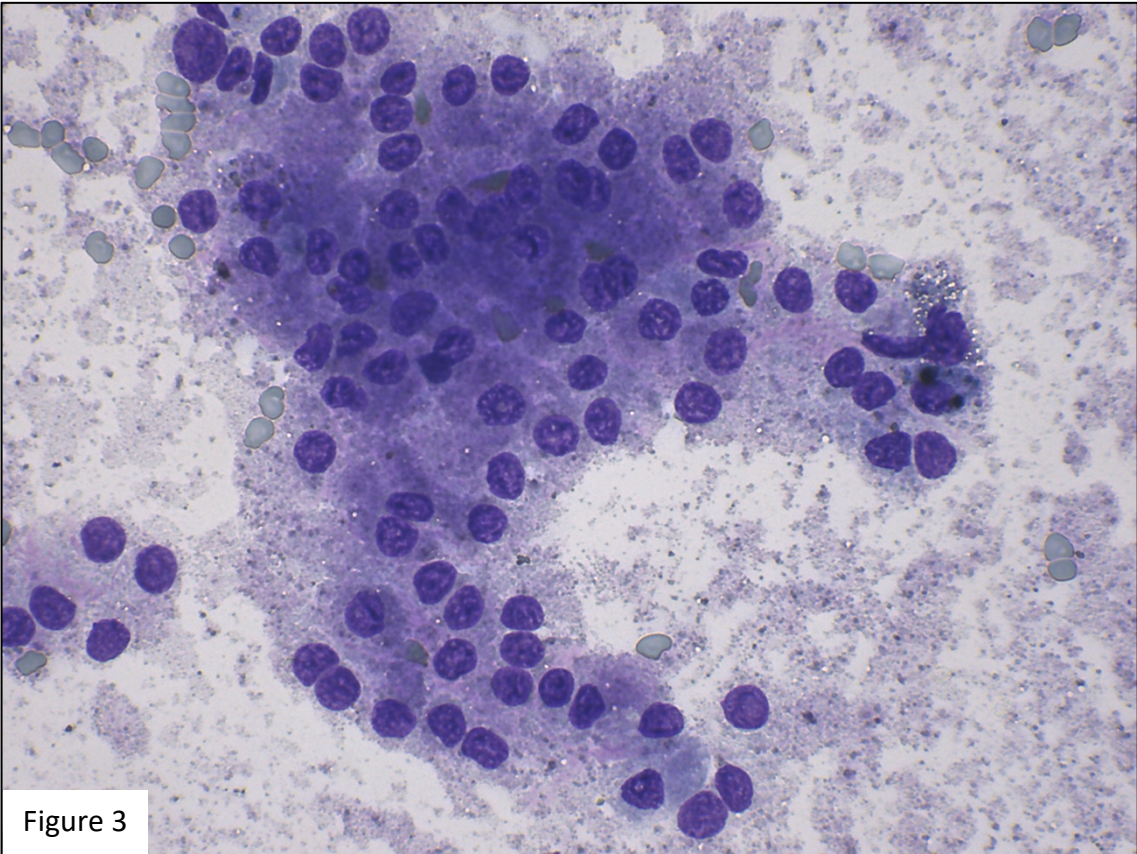


Figure 5: cytological photomicrograph of the testicular mass. Aqueous Romanowsky stain, ×100x objective.

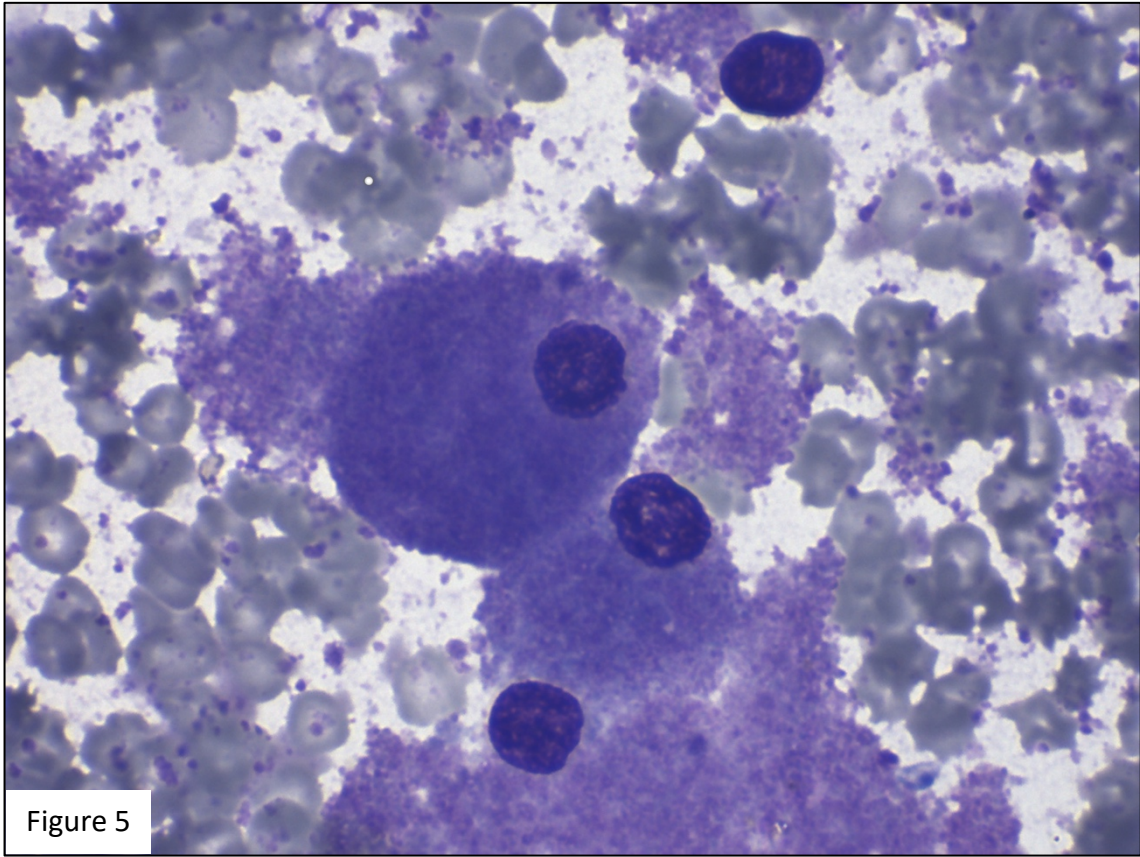


Figure 5